

Effect of Pelvic Fin Ray Removal on Survival and Growth of Bull Trout

NIKOLAS D. ZYMONAS*¹ AND THOMAS E. McMAHON

Ecology Department, Fish and Wildlife Program, Montana State University, Bozeman, Montana 59717, USA

Abstract.—Fin rays offer a viable alternative to scales and otoliths for determining ages of threatened salmonids, but information on potential side effects from their removal is limited. We conducted a laboratory study to assess the effects of removal of three pelvic fin rays on the survival and growth of two age-groups of bull trout *Salvelinus confluentus* (age 3: 209–298 mm standard length [SL]; age 4: 294–362 mm SL). Survival was similar between fin-ray-excised fish ($\geq 73\%$) and control fish ($\geq 69\%$) at each stage during the 169-d study ($P > 0.85$). Survival was also similar within age-3 (fin ray excision: $\geq 39\%$; control: $\geq 30\%$; $P > 0.42$) and age-4 bull trout (fin ray excision: $\geq 94\%$; control: $\geq 94\%$; $P > 0.86$), although a bacterial coldwater infection disproportionately caused higher mortality in age-3 fish for both test groups. Growth also did not differ between treatment and control groups of either age-3 or age-4 fish ($P > 0.38$). The fin excision wound was completely healed in 56% of treatment fish by day 33 and in 96% by day 126. Excised fin rays regenerated at the rate of 0.25% per day in 92% of treatment fish, attaining nearly one-half (42%) of the estimated total length by the end of the study; 90% regeneration was predicted to occur in about 13 months. Results suggest that removal of pelvic fin rays for aging is probably not deleterious to bull trout over the size range examined.

Partial or complete fin removal is widely used in fisheries studies to mark fish (Guy et al. 1996) and to obtain rays or spines for analyses of age and growth (DeVries and Frie 1996). In many species, especially charrs (*Salvelinus* spp.), otoliths and fin rays have greater aging precision than scales, particularly for long-lived individuals (e.g., Dutil and Power 1977; Sharp and Bernard 1988; Williamson and Macdonald 1997; Nakamura et al. 1998; but see Hubert et al. 1987). Fin rays have been validated for aging several salmonids, including brown trout *Salmo trutta* (Burnet 1969; Shirvell 1981) and Chinook salmon *Oncorhynchus tshawytscha* (Chilton and Bilton 1986). Fin rays may be a useful alternative to otoliths for aging analysis in situations requiring a nonlethal sampling technique, such as in studies of threatened species.

However, fin ray removal may be an unacceptable aging technique if it impairs growth or survival of rare species (Collins and Smith 1996).

Potential adverse effects of fin removal include a short-term physiological stress response (Sharpe et al. 1998) and infection at the removal site (Fry 1961). Potential longer-term impairments include reduced station-holding ability (Arnold et al. 1991), reduced growth (Saunders and Allen 1967; Skaugstad 1990), and reduced survival (Ricker 1949; Coble 1971; Nicola and Cordone 1973; Vincent-Lang 1993), although the manifestation of these effects varies considerably, depending on degree of fin removal and regeneration and on the particular fin, species, and size-class studied (Mears and Hatch 1976; Bergstedt 1985).

We investigated whether excision of the first three rays of one pelvic fin for the purpose of age and growth estimation was deleterious to bull trout *Salvelinus confluentus*. Bull trout are federally listed as a threatened species in the conterminous United States (U.S. Office of the Federal Register 1999), and strict restrictions are placed on the number of fish that can be killed for scientific or other purposes, hence limiting the use of lethal sampling techniques such as otolith removal. Fin rays of bull trout offer an ostensibly nonlethal aging alternative to otoliths while offering greater aging precision and better resolution of annuli in older fish than do scales (Williamson and Macdonald 1997; Gust 2001). However, the effect of removing only a few rays in bull trout or other salmonids has not been reported in the literature. To date, studies of pelvic fin excision in salmonids have addressed only its complete removal (e.g., Shetter 1951; Skaugstad 1990). In this study, we examined the effects of fin ray excision on growth, survival, and fin regeneration in bull trout 209–362 mm standard length (SL) in the laboratory over a 169-d period, which is about the length of a normal growing season.

Methods

Bull trout used in this study were part of a cultured population at the U.S. Fish and Wildlife Service's Bozeman Fish Technology Center, Bozeman, Montana. Fertilized eggs were originally obtained from a captive broodstock at the Creston National Fish

* Corresponding author: nik.zymonas@state.nm.us

¹ Present address: New Mexico Department of Game and Fish, Conservation Services Division, Post Office Box 25112, Santa Fe, New Mexico 87504, USA.

Received July 25, 2005; accepted May 1, 2006

Published online November 20, 2006

Hatchery, Montana, and raised for use in a temperature study (Selong et al. 2001). Fin erosion was present on dorsal and caudal fins of most individuals, but the pelvic fins were largely intact.

Before the start of the study, bull trout developed symptoms of bacterial coldwater disease (caused by *Flavobacterium psychrophilum*), a common yet difficult-to-control infection in hatcheries (Nematollahi et al. 2003). Disease symptoms included lesions on or near the caudal peduncle, deterioration of the caudal fin, and continual swimming near the surface. About 14% of bull trout died after the onset of coldwater disease symptoms, and the study was delayed by about 2 months until the source of infection was positively identified and mortality ceased. Because all fish had been similarly exposed to the pathogen before beginning this experiment, the initial condition of control versus treatment groups was deemed unbiased. Fin excision can increase susceptibility to a pathogen (Fry 1961), and the infection was considered an added stressor that was more likely to have an adverse effect on fin-excised fish than control fish. Considered to be naturally ubiquitous in bull trout waters in Montana (E. Ryce, Montana Fish, Wildlife, and Parks, personal communication), the coldwater disease pathogen represented a realistic threat encountered by wild fish.

Our experimental design enabled comparison of treatment and control groups among all fish as well as by age-class. Two age-classes were examined: age 3 ($N = 33$; initial mean \pm SD = 258 ± 23 mm SL; range = 209–298 mm) and age 4 ($N = 50$; 335 ± 16 mm SL; range = 294–362 mm). Age-3 individuals were representative of the size of adult bull trout residing in small headwater streams or migratory subadults occupying larger rivers or lakes, whereas age-4 fish were similar in size to large resident or small migratory adults. At the start of the experiment, fish were anesthetized with tricaine methanesulfonate (MS-222), weighed to the nearest 0.1 g, and measured for SL to the nearest millimeter. A visual implant (VI) tag was inserted in the adipose tissue behind each eye, providing unique identification of the fish without affecting growth or survival (Zerrenner et al. 1997; Rikardsen et al. 2002). Individuals were randomly selected for fin excision, which involved excising the first three rays at the anterior edge of the left pelvic fin with surgical scissors. Fin rays were cut below the articulation with the basipterygium, but as close to the base of the ray as possible to produce maximum severity of removal and to ensure inclusion of the early growth portion of the ray necessary for accurate age determination (Scidmore and Glass 1953; Chilton and Bilton 1986). Excision of the leading three rays removed about one-third of the pelvic fin.

Nearly equal proportions of treatment and control bull trout were randomly placed into three circular fiberglass tanks (diameter = 1.2 m; flow rate = 23.8 L/min) to attain replicate compositions of six treatment and five control age-3 fish per tank, and nine treatment and seven or eight control age-4 fish per tank. Length distributions of treatment and control fish were similar within both age-3 ($t = 0.57$, $df = 23$, $P = 0.57$) and age-4 ($t = 0.68$, $df = 43$, $P = 0.50$) groups at the beginning of the experiment. Water temperature was maintained at constant 12°C, and food rations approximating satiation levels (Selong et al. 2001) were added by hand once daily.

We measured fish growth, survival, and fin ray regeneration after 1 week and thereafter at approximately monthly intervals (34, 64, 99, 127, and 169 d) over a 5.5-month period. Fish were anesthetized, identified by VI tag code, weighed, and measured at each sampling date. The condition of the fin excision wound was visually inspected and the degree of tissue inflammation (none, moderate, or severe) was recorded. Length of regeneration of excised rays was quantified with ruler measurements to the nearest millimeter. Because regeneration was uneven across rays, we used the average length of the regenerating fin portion in analyses. To adjust for growth during the study, we converted the length of fin regeneration to a percentage of total estimated fin length. Total estimated fin length was derived from an equation relating pelvic fin length (PFL) and body length (BL): $PFL = 0.141BL - 11.7$ ($r^2 = 0.72$; $P = 0.01$). The equation was obtained by regressing maximum length of the left pelvic fin (typically the second or third ray) on body length ($N = 38$).

All statistical analyses were conducted with Minitab software (Minitab, Inc., State College, Pennsylvania) with the level of significance α set at 0.05. Chi-square tests were used to test for a tank effect on survival and growth of control and fin ray excision groups. Survival differences between control and fin ray excision groups at each sampling were also evaluated with chi-square tests or with Fisher's exact tests if expected cell counts were less than five (Zar 1996). Effects of treatment, age-group, and tank on relative growth ($[\text{end length} - \text{initial length}]/\text{initial length}$; Busaker et al. 1990) at each sampling were analyzed with a model 1 analysis of variance (ANOVA). A t -test was used to examine differences between age-groups in the amount of fin regeneration attained by the end of the study.

Water circulation failed in one tank on day 108, causing visible distress and increased mortality. Data collected from this tank after the previous sample date (day 99) were subsequently omitted from further analysis. Results for all tanks were combined for

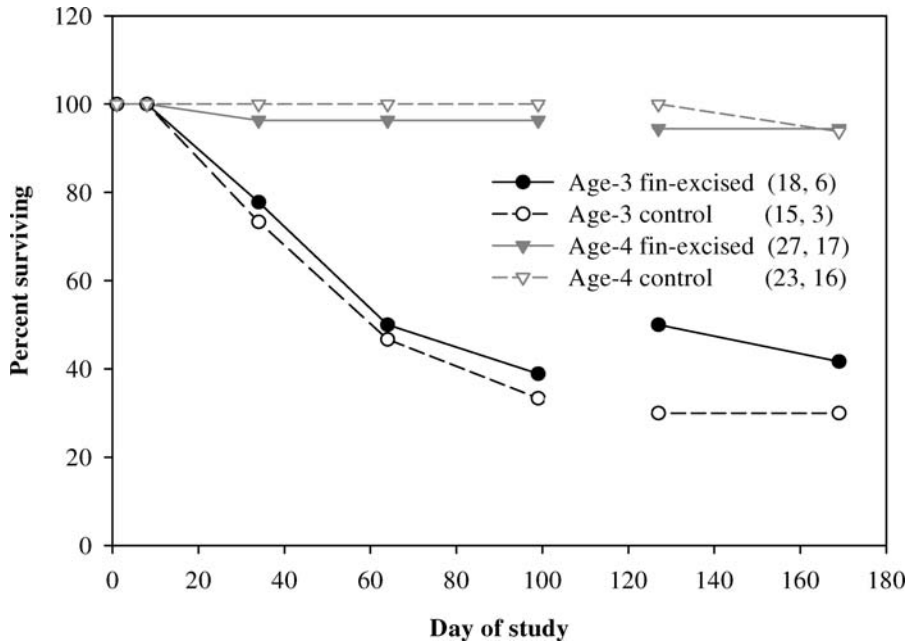


FIGURE 1.—Percent survival of age-3 and age-4 bull trout subjected to excision of fin rays and percent survival of control fish (no excision) during a 169-d laboratory study. Percent survival is shown for all three test tanks from day 1 to 99 and for the two tanks unaffected by a water supply failure from day 127 to 169. The first number in parentheses is the initial sample size for each age and treatment group for all three tanks; the second number is the sample size of the remaining two tanks at day 127.

analyses because tank effects on survival (day 99: $\chi^2 = 0.19$, $df = 2$, $P = 0.91$; day 169: $\chi^2 = 0.08$, $df = 1$, $P = 0.78$) and growth (day 99: $F = 1.06$, $df = 2$, $P = 0.36$; day 169: $F = 0.09$, $df = 1$, $P = 0.77$) were not significantly different.

Results

Overall survival averaged 75% by day 99 for all three tanks and 71% by day 169 in the two tanks without water circulation failure (Figure 1). No mortality occurred before the first examination on day 8. Survival was similar between fin ray excision and control groups at each stage during the 169-d study (fin ray excision: $\geq 73\%$; control: $\geq 69\%$; $P > 0.85$). Survival differed significantly between age-classes from day 34 through the end of the study ($P < 0.02$). At the end of the study, 94% ($N = 32$) of age-4 bull trout remained alive in the two unaffected tanks but only 36% ($N = 8$) of age-3 fish remained alive. Symptoms of advanced coldwater disease, namely lesions on the caudal fin and peduncle, were readily apparent in at least 58% of the age-3 mortalities (this represents a minimum value because some mortalities were not inspected before disposal) and in 40% of survivors. Despite differences in survival between the two age-classes, fin ray excision did not affect survival

within each age-class (age 3: $P > 0.42$; age 4: $P > 0.86$). Statistical comparisons within the age-3 group after day 99 should be regarded with caution because only three control and five fin-excised fish survived to the end of the experiment; nonetheless, nearly equal proportions of fin ray excision and control fish survived in both the age-3 and age-4 groups at each sampling date (Figure 1).

Relative growth in length attained at the end of the study was 12.5% (mean \pm SE = 31 ± 4 mm) for the age-3 group and 4.5% (15 ± 1 mm) for the age-4 group (Figure 2). Fin ray excision did not affect growth at any point during the course of the study ($P > 0.38$). Although age-3 bull trout experienced high mortality, the relative growth of treatment and control fish was similar in all three tanks at day 99 (fin ray excision: $7.6 \pm 0.8\%$; control: $7.6 \pm 1.0\%$) and in the two unaffected tanks at the end of the study on day 169 (fin ray excision: $12.9 \pm 1.8\%$; control: $11.9 \pm 2.2\%$).

Moderate to severe inflammation was observed at the excision site in 46% of fin-excised fish on day 8 but declined to 4% by day 34. The excision wound was completely healed in 56% of treated fish by day 34 and in 96% by day 127. At the end of the study, the mean percentage of estimated total fin length regenerated was 42%, yielding a regeneration rate of 0.25% per day

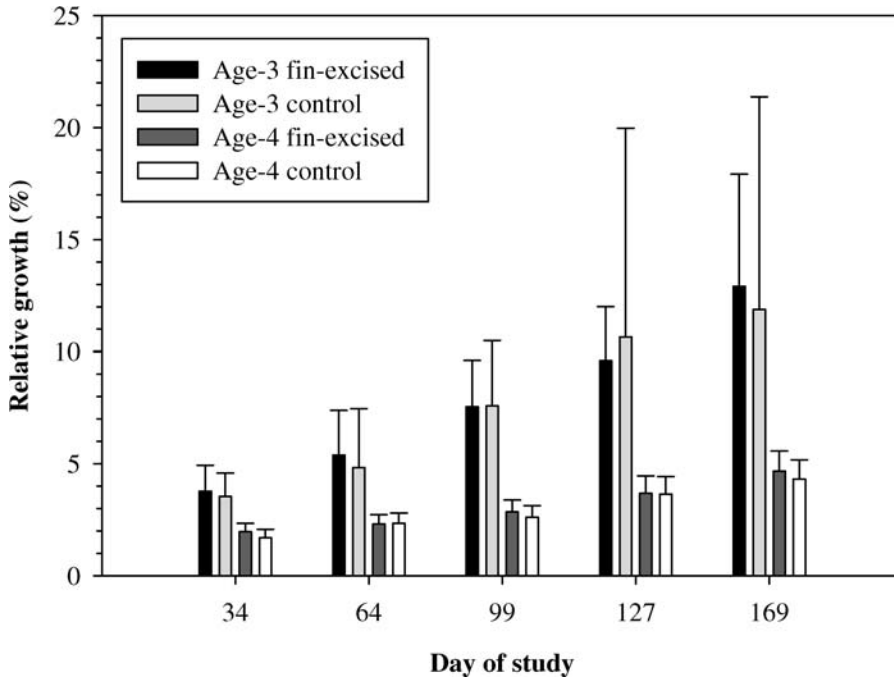


FIGURE 2.—Mean relative growth (%) in standard length (with upper 95% confidence limit) of age-3 and age-4 bull trout subjected to fin ray excision and mean relative growth of control fish (no excision) over the course of a 169-d laboratory study. Only data from the two tanks unaffected by water supply failure are included for days 127 and 169.

(Figure 3). Regeneration did not differ between age-classes ($t = 0.17$, $df = 7$, $P = 0.87$), and the regenerated fin portion appeared normal in 92% (22 of 24) of surviving fin ray excision fish. There were two cases of aberrant regeneration: one fish in which only one of the three excised rays regenerated, and another fish in which the regenerated rays were sharply bent. We estimated that 90% fin regeneration would take about 370 d, assuming a linear regeneration rate (mean percent regeneration = $0.0132 + 0.0024[\text{days}]$; $r^2 = 0.93$, $P = 0.001$; Figure 3).

Discussion

We found no evidence that the removal of pelvic fin rays harmed captive bull trout. The lack of mortality in the 7-d period after fin ray excision and the rapid decline in inflammation suggested that stress and injury from handling (Ricker 1949; Sharpe et al. 1998) were not severe. Long-term stress or physical impairment caused by fin ray excision was also apparently not great enough to adversely effect survival or growth, because the proportion of fin ray excised fish to control fish remained nearly equal during the entire experiment and growth was similar between control and treatment fish. These findings agree with numerous previous

studies wherein the (more severe) complete removal of a paired fin did not adversely affect survival or growth (reviewed in Bergstedt 1985; Pratt and Fox 2002).

Two factors potentially contributed to lower survival of age-3 bull trout. First, the age-3 fish appeared to be more susceptible to coldwater disease, which is typically more prevalent in smaller fish (Nematollahi et al. 2003). Second, an unanticipated additional stress may have been placed on the age-3 fish by cohabitation with the larger age-4 fish. Before the experiment began, the two age-groups were housed in separate tanks. After age-classes were mixed at the start of the trial, smaller fish frequently occupied the upper portion of the water column, whereas larger fish rested near the bottom. However, the surviving age-3 fish grew well, no agonistic behavior was observed, and the age-3 fish were too large to represent potential prey for the age-4 fish. Whatever factor selectively affected the smaller fish, we found no evidence that it differentially influenced survival of fin ray excision and control groups.

The presence of the coldwater disease pathogen, which occurs naturally in bull trout waters, was considered a potential stressor that could disproportionately affect fin-excised fish. Elevated infection

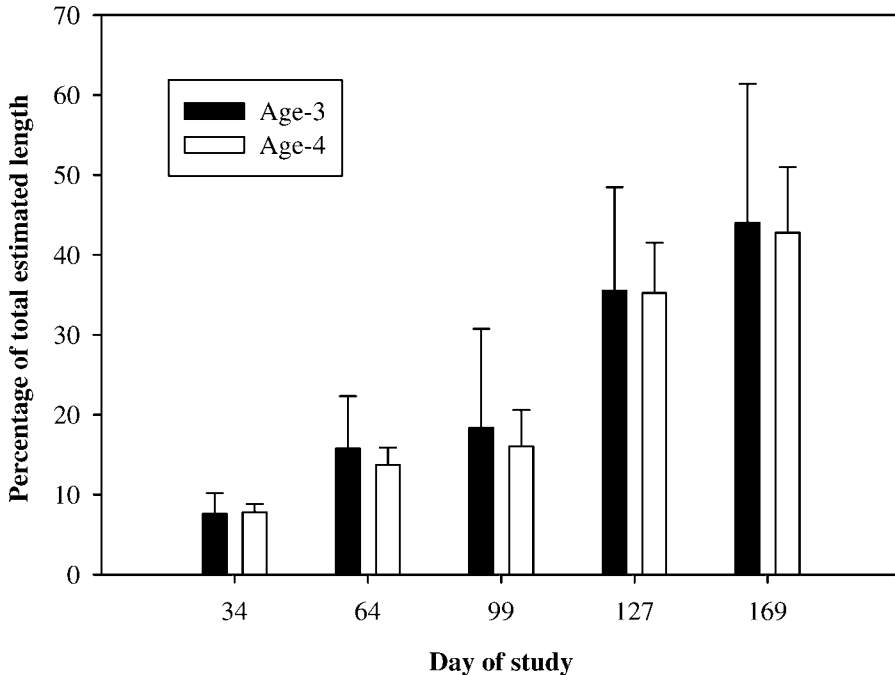


FIGURE 3.—Regeneration of excised pelvic fin rays, expressed as a percentage of the total estimated length of the fin rays, in age-3 and age-4 bull trout over time during a 169-d laboratory study.

rates have been linked to fin excision in previous studies (Fry 1961), but no difference was evident in our experiment. The coldwater disease infection was apparently not severe enough to mask the effect of fin ray excision, given the near complete survival of the age-4 group and similar survival rates across treatments within age-groups. The specific mechanism of infection has not been conclusively identified for coldwater disease (Nematollahi et al. 2003), but the open wound caused by fin excision did not appear to be the main portal for new infection in our study because both control and treatment fish exhibited disease symptoms.

The fin regeneration rate observed in this study was similar to that in previous studies, which have reported nearly complete regeneration within 1 year (Stuart 1958; Eipper and Forney 1965; Coombs et al. 1990; Thompson and Blankenship 1997). Regeneration is typically more rapid and complete as the proportion of fin ray removed decreases (Eipper and Forney 1965; Thompson and Blankenship 1997) and as the amount of nervous tissue remaining increases (Geraudie and Singer 1985). Despite the close proximity of the fin ray excision to the body, we observed normal fin regeneration rates in nearly all test fish, and complete regeneration was projected to occur at approximately 13 months. This projection may underestimate the time required in the wild because our study was conducted

under controlled conditions. A wild bull trout recaptured from Rock Creek near Noxon, Montana, 413 d after the partial excision of pelvic fin ray identical to that used in our study, showed 75% fin regeneration (0.18% per day), slightly lower than the 0.25% per day we observed in the laboratory.

The absence of a significant reduction in survival or growth of fin-excised bull trout in our study, coupled with relatively rapid regeneration of excised rays, suggests that partial pelvic fin removal for aging is probably not deleterious to bull trout. However, further evaluation is warranted because we did not evaluate fin ray excision effects on smaller juveniles (<200 mm SL) or large adults (>362 mm SL). We also recommend monitoring the growth and fin regeneration of fin-excised fish in the field to verify our laboratory findings. Pelvic fin excision could reduce growth or survival of bull trout in the wild by affecting their ability to elude predators, capture prey, maneuver, or withstand pathogens (Ricker 1949; Coble 1967; Nicola and Cordone 1973). However, the pelvic fins are generally less critical to swim performance and maneuverability than other fins (McNeil and Crossman 1979). Removal of only a few leading rays of the pelvic fin should minimize detriment to the fish by allowing a level of continued functionality and reducing the area requiring subsequent regeneration.

Acknowledgments

Funding for this study was provided by AVISTA Corporation and the U.S. Fish and Wildlife Service. We thank Ginger Gillan, Larry Lockard, and especially Joe DosSantos, for project support. Matt Toner, Greg Kindschi, Ron Zitzow, and other staff of the U.S. Fish and Wildlife Service's Bozeman Fish Technology Center graciously provided laboratory facilities and operational assistance. The efforts of Wade Fredenberg, Creston National Fish Hatchery, to maintain a hatchery broodstock of bull trout made this study possible. We thank Andrew Munro for advice on study design and other support, and Drake Burford, Adam Craig, Chris Jerde, and Clint Sestrich for technical assistance. Chris Downs, Laura Katzman, Brad Liermann, Sean Moran, and two anonymous reviewers provided helpful comments on the manuscript.

References

- Arnold, G. P., P. W. Webb, and B. H. Holford. 1991. The role of the pectoral fins in station-holding of Atlantic salmon parr (*Salmo salar* L.). *Journal of Experimental Biology* 156:625–629.
- Bergstedt, R. 1985. Mortality of fish marked by fin clipping: an annotated bibliography, 1934–1981. U.S. Fish and Wildlife Service, Great Lakes Fishery Laboratory, Administrative Report 85-3, Ann Arbor, Michigan.
- Burnet, A. M. R. 1969. An examination of the use of scales and fin rays for age determination of brown trout (*Salmo trutta* L.). *New Zealand Journal of Marine and Freshwater Research* 3:147–151.
- Busaker, G. P., I. A. Adelman, and E. M. Goolish. 1990. Growth. Pages 363–377 in C. B. Schreck and P. B. Moyle, editors. *Methods for fish biology*. American Fisheries Society, Bethesda, Maryland.
- Chilton, D. E., and H. T. Bilton. 1986. New method for ageing Chinook salmon (*Oncorhynchus tshawytscha*) using dorsal fin rays, and evidence of its validity. *Canadian Journal of Fisheries and Aquatic Sciences* 43:1588–1594.
- Coble, D. W. 1967. Effects of fin clipping on mortality and growth of yellow perch with a review of similar investigations. *Journal of Wildlife Management* 31:173–180.
- Coble, D. W. 1971. Effects of fin clipping and other factors on survival and growth of smallmouth bass. *Transactions of the American Fisheries Society* 100:460–473.
- Collins, M. R., and T. I. J. Smith. 1996. Sturgeon fin ray removal is nondeleterious. *North American Journal of Fisheries Management* 16:939–941.
- Coombs, K. A., J. K. Bailey, C. M. Herbing, and G. W. Friars. 1990. Evaluation of various external marking techniques for Atlantic salmon. Pages 142–146 in N. C. Parker, A. E. Giorgi, R. C. Heidinger, D. B. Jester, Jr., E. D. Prince, and G. A. Winans, editors. *Fish-marking techniques*. American Fisheries Society, Symposium 7, Bethesda, Maryland.
- DeVries, D. R., and R. V. Frie. 1996. Determination of age and growth. Pages 483–512 in B. R. Murphy and D. W. Willis, editors. *Fisheries techniques*, 2nd edition. American Fisheries Society, Bethesda, Maryland.
- Dutil, J. D., and G. Power. 1977. Validity of reading otoliths compared to reading scales for determination of age of brook trout (*Salvelinus fontinalis*). *Naturaliste Canadien* 104:361–367.
- Eipper, A. W., and J. L. Forney. 1965. Evaluation of partial fin clips for marking largemouth bass, walleyes, and rainbow trout. *New York Fish and Game Journal* 12:233–240.
- Fry, D. H., Jr. 1961. Some problems in the marking of salmonids. *Pacific Marine Fisheries Commission Bulletin* 5:77–83.
- Geraudie, J., and M. Singer. 1985. Necessity of an adequate nerve supply for regeneration of the amputated pectoral fin in the teleost *Fundulus*. *Journal of Experimental Zoology* 234:367–374.
- Gust, J. J. 2001. Comparison of methods to estimate the ages of bull trout in the St. Mary River drainage, and an estimate of growth rates from scales. Master's thesis. Montana State University, Bozeman.
- Guy, C. S., H. L. Blankenship, and L. A. Nielsen. 1996. Tagging and marking. Pages 353–383 in B. R. Murphy and D. W. Willis, editors. *Fisheries techniques*, 2nd edition. American Fisheries Society, Bethesda, Maryland.
- Hubert, W. A., G. T. Baxter, and M. Harrington. 1987. Comparison of age determinations based on scales, otoliths, and fin rays for cutthroat trout from Yellowstone Lake. *Northwest Science* 61:32–36.
- McNeil, F. I., and E. J. Crossman. 1979. Fin clips in the evaluation of stocking programs for muskellunge, *Esox masquinongy*. *Transactions of the American Fisheries Society* 108:335–343.
- Mears, H. C., and R. W. Hatch. 1976. Overwinter survival of fingerling brook trout with single and multiple fin clips. *Transactions of the American Fisheries Society* 105:669–674.
- Nakamura, T., T. Maruyama, and S. Watanabe. 1998. Validity of age determination in the fluvial Japanese charr *Salvelinus leucomaenis* by scale reading. *Fisheries Science* 64:385–387.
- Nematollahi, A., A. Decostere, F. Pasmans, and F. Haesebrouck. 2003. *Flavobacterium psychrophilum* infections in salmonid fish. *Journal of Fish Diseases* 26:563–574.
- Nicola, S. J., and A. J. Cordone. 1973. Effects of fin removal on survival and growth of rainbow trout (*Salmo gairdneri*) in a natural environment. *Transactions of the American Fisheries Society* 102:753–758.
- Pratt, T. C., and M. G. Fox. 2002. Effect of fin clipping on overwinter growth and survival of age-0 walleyes. *North American Journal of Fisheries Management* 22:1290–1294.
- Ricker, W. E. 1949. Effects of removal of fins upon growth and survival of spiny-rayed fishes. *Journal of Wildlife Management* 13:29–40.
- Rikardsen, A. H., M. Woodgate, and D. A. Thompson. 2002. A comparison of Floy and soft V1 alpha tags on hatchery Arctic charr, with emphasis on tag retention, growth, and survival. *Environmental Biology of Fishes* 64:269–273.
- Saunders, R. L., and K. R. Allen. 1967. Effects of tagging and of fin clipping on the survival and growth of Atlantic

- salmon between smolt and adult stages. *Journal of the Fisheries Research Board of Canada* 24:2595–2611.
- Scidmore, W. J., and A. W. Glass. 1953. Use of pectoral fin rays to determine age of the white sucker. *Progressive Fish-Culturist* 15:114–115.
- Selong, J. H., T. E. McMahon, A. V. Zale, and F. T. Barrows. 2001. Effect of temperature on survival and growth of bull trout, with application of an improved method for determining thermal tolerance in fishes. *Transactions of the American Fisheries Society* 130:1026–1037.
- Sharp, D., and D. R. Bernard. 1988. Precision of estimated ages of lake trout from five calcified structures. *North American Journal of Fisheries Management* 8:367–372.
- Sharpe, C. S., D. A. Thompson, H. L. Blankenship, and C. B. Schreck. 1998. Effects of routine handling and tagging procedures on physiological stress responses in juvenile chinook salmon. *Progressive Fish-Culturist* 60:81–87.
- Shetter, D. S. 1951. The effect of fin removal on fingerling lake trout (*Cristivomer namaycush*). *Transactions of the American Fisheries Society* 80:260–277.
- Shirvell, C. S. 1981. Validity of fin ray ageing for brown trout. *Journal of Fish Biology* 18:377–383.
- Skaugstad, C. 1990. Effects of fin removal on survival and growth of Arctic char in a hatchery environment. Alaska Department of Fish and Game, Fishery Data Series 90-28, Anchorage.
- Stuart, T. A. 1958. Marking and regeneration of fins. Scottish Home Department, Freshwater and Salmon Fisheries Research Publication 22, Edinburgh.
- Thompson, D. A., and H. L. Blankenship. 1997. Regeneration of adipose fins given complete and incomplete clips. *North American Journal of Fisheries Management* 17:467–469.
- Vincent-Lang, D. 1993. Relative survival of unmarked and fin-clipped coho salmon from Bear Lake, Alaska. *Progressive Fish-Culturist* 55:141–148.
- U.S. Office of the Federal Register. 1999. Determination of threatened status for bull trout in the conterminous United States, *Federal Register* 64:210 (1 November 1999):58909–58936.
- Williamson, C. J., and J. S. Macdonald. 1997. The use of three ageing techniques to estimate the growth rates for rainbow trout (*Oncorhynchus mykiss*) and bull trout (*Salvelinus confluentus*) from selected locations near Takla Lake, B.C. Canada Fisheries and Marine Service Technical Report 2191.
- Zar, J. H. 1996. *Biostatistical analysis*, 3rd edition. Prentice-Hall, Englewood Cliffs, New Jersey.
- Zerrenner, A., D. C. Josephson, and C. C. Krueger. 1997. Growth, mortality, and mark retention of hatchery brook trout marked with visible implant tags, jaw tags, and adipose fin clips. *Progressive Fish-Culturist* 59:241–245.